



ELSEVIER

Available online at www.sciencedirect.com

ScienceDirect

Neuromuscular Disorders xxx (2014) xxx–xxx

www.elsevier.com/locate/nmd

Exome sequencing identifies a *DNAJB6* mutation in a family with dominantly-inherited limb-girdle muscular dystrophy

Julien Couthouis^{a,1}, Alya R. Raphael^{a,1}, Carly Siskind^{b,1}, Andrew R. Findlay^{c,2}, Jason D. Buenrostro^a, William J. Greenleaf^a, Hannes Vogel^{d,e}, John W. Day^f, Kevin M. Flanigan^{c,g,h}, Aaron D. Gitler^{a,*}

^a Department of Genetics, Stanford University School of Medicine, Stanford, CA, USA

^b Neuroscience Center, Stanford Hospital and Clinics, Stanford, CA, USA

^c Department of Neurology, The Ohio State University, Columbus, OH, USA

^d Departments of Pathology, Stanford University School of Medicine, Stanford, CA, USA

^e Departments of Pediatrics, Stanford University School of Medicine, Stanford, CA, USA

^f Department of Neurology, Stanford University School of Medicine, Stanford, CA, USA

^g Department of Pediatrics, The Ohio State University, Columbus, OH, USA

^h Center for Gene Therapy, Nationwide Children's Hospital, Columbus, OH, USA

Received 20 December 2013; received in revised form 27 January 2014; accepted 31 January 2014

Abstract

Limb-girdle muscular dystrophy primarily affects the muscles of the hips and shoulders (the “limb-girdle” muscles), although it is a heterogeneous disorder that can present with varying symptoms. There is currently no cure. We sought to identify the genetic basis of limb-girdle muscular dystrophy type 1 in an American family of Northern European descent using exome sequencing. Exome sequencing was performed on DNA samples from two affected siblings and one unaffected sibling and resulted in the identification of eleven candidate mutations that co-segregated with the disease. Notably, this list included a previously reported mutation in *DNAJB6*, p.Phe89Ile, which was recently identified as a cause of limb-girdle muscular dystrophy type 1D. Additional family members were Sanger sequenced and the mutation in *DNAJB6* was only found in affected individuals. Subsequent haplotype analysis indicated that this *DNAJB6* p.Phe89Ile mutation likely arose independently of the previously reported mutation. Since other published mutations are located close by in the G/F domain of *DNAJB6*, this suggests that the area may represent a mutational hotspot. Exome sequencing provided an unbiased and effective method for identifying the genetic etiology of limb-girdle muscular dystrophy type 1 in a previously genetically uncharacterized family. This work further confirms the causative role of *DNAJB6* mutations in limb-girdle muscular dystrophy type 1D.

© 2014 Elsevier B.V. All rights reserved.

Keywords: Limb-girdle muscular dystrophy; *DNAJB6*; Exome sequencing

1. Introduction

Autosomal dominant limb-girdle muscular dystrophies (LGMD1) are a genetically and clinically heterogeneous group of disorders. LGMD1 often presents with progressive proximal muscle weakness of the upper and lower extremities; however several forms may present

* Corresponding author. Address: 300 Pasteur Drive, M322 Alway Building, Stanford, CA 94305, USA. Tel.: +1 (650) 725 6991; fax: +1 (650) 725 1534.

E-mail address: agitler@stanford.edu (A.D. Gitler).

¹ These authors contributed equally to the manuscript.

² Current address: University of California Irvine School of Medicine, Irvine, CA, USA.

<http://dx.doi.org/10.1016/j.nmd.2014.01.014>

0960-8966/© 2014 Elsevier B.V. All rights reserved.

with primarily distal weakness, and clinical heterogeneity may exist even within the same family [1]. To date, mutations in five causative genes have been associated with LGMD1, including the *MYOT* gene encoding myotilin in LGMD1A [2], the *LMNA* gene encoding lamin A/C in LGMD1B [3], the *CAV3* gene which encodes caveolin in LGMD1C [4]. More recently, mutations in the *DNAJB6* gene have been described in LGMD1D patients [5–7] and mutations in *Transportin 3* (*TNPO3*) gene have been linked to LGMD1F [8,9]. Additional loci linked to LGMD1 have been mapped, but causative genes have not been identified [1].

Using exome sequencing, we sought to determine the genetic basis for LGMD1 in an American family of Northern European descent that presented with an autosomal dominant pattern of inheritance. Exome sequencing has been used to great effect to identify the underlying mutations in a number of diseases, including recently in LGMD1 [5,8].

2. Patients and methods

All aspects of this study were approved by the Stanford University Institutional Review Board and written informed consent was received.

Proband (III-3, Fig. 1A arrowhead) presented at 55 years of age to clinic, with a history of slow running and difficulty climbing stairs, beginning shortly after high school. He began using a cane in his late 30s, two canes in his 40s, and at 56 years of age, developed acute worsening of upper and lower extremity strength owing to severe cervical spinal cord stenosis and subsequently became wheelchair dependent. A left biceps muscle biopsy at 32 years of age revealed marked variation in fiber size, scattered fibers with single or multiple rimmed vacuoles (Fig 2A, B), as well as several angular atrophic fibers characteristic of neurogenic atrophy (Fig. 2C). There were normal amounts of connective and adipose tissue and no increase in central nuclei or fiber splitting. Examination showed marked weakness of shoulder abduction, elbow flexion, hip flexion and extension, and ankle plantar flexion. Ankle dorsiflexion strength was normal, but there was moderately severe weakness of intrinsic hand muscles and deep finger flexors. An EKG

and echocardiogram at 54 years of age were normal. He has mild dyspnea and sleep-disordered breathing for which he required positive airway pressure support, with a forced vital capacity that was 42% of predicted. Genetic testing for LGMD1 genes *MYOT*, *CAV3* and *LMNA* was negative.

The proband's son (IV-6, Fig. 1A) was evaluated by a neuromuscular specialist at 28 years of age due to a history of difficulty climbing stairs and rising from a sitting position beginning around age 16, although slow running was noted as early as age 8. Physical examination revealed proximal greater than distal weakness affecting the lower extremities more than the upper, with prominent atrophy of the thigh adductors and the medial head of gastrocnemius, scapular winging, and Achilles tendon contractures (summarized in Table 1). He does not use assistive devices, and an EKG was normal at time of presentation.

Proband pedigree analysis was consistent with autosomal dominant inheritance (Fig. 1).

2.1. Exome sequencing

Genomic DNA samples were isolated from three family members using Oragene•DISCOVER (OGR-500) saliva collection kits; the three remaining DNA samples were sent from Prevention Genetics (Marshfield, WI). Exomes were generated for three family members using the SureSelect Human All Exon 50 Mb kit (Agilent, Santa Clara, CA). Sequencing was performed with 250 bp paired-end reads on an Illumina MiSeq platform (Illumina Inc., San Diego, CA). Reads were aligned to the human reference genome (UCSC hg19, GRCh37, Feb. 2009 release) using bowtie2 [10] and SAMtools [11]. We applied GATK base quality score recalibration, indel realignment, duplicate removal, and performed coverage calculations, SNP and INDEL discovery and genotyping across each sample using standard hard filtering parameters or variant quality score recalibration [12]. Variants were filtered against dbSNPv137, 1000 genomes and ESP 6500 databases and were then annotated using ANNOVAR [13]. We assessed segregation of candidate mutations by Sanger sequencing using standard methods in all six family members for which DNA was available.

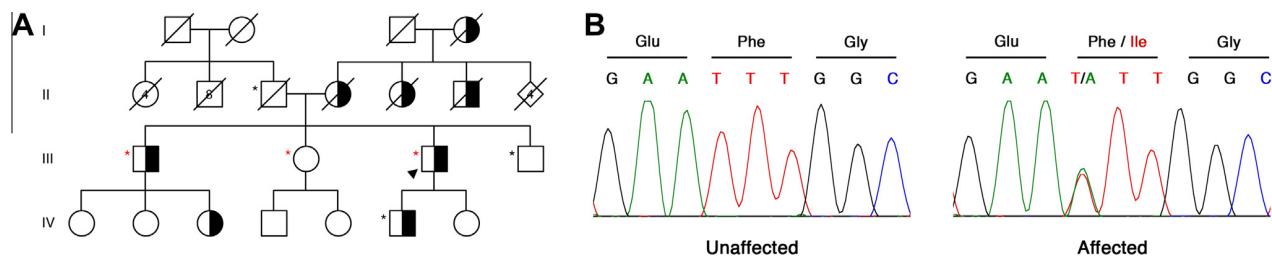


Fig. 1. Mutations in *DNAJB6* cause LGMD1D. (A) An American family of Northern European descent with LGMD1. Exome sequencing was performed in individuals marked with a red asterisk, Sanger sequencing in those with a black asterisk. Proband is indicated by black arrowhead. Affected individuals are colored black and white to indicate dominant inheritance. (B) A c.265T>A mutation was discovered only in affected patients in the *DNAJB6* gene, resulting in a p.Phe89Ile amino acid substitution.

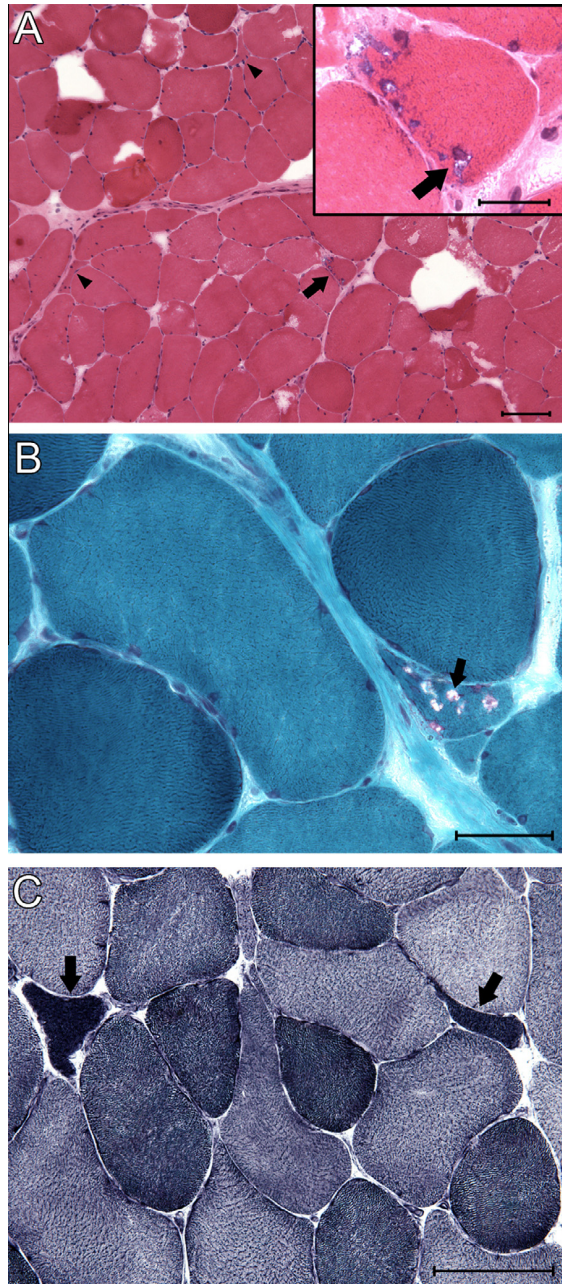


Fig. 2. Histopathological examination of LGMD1D muscle biopsy. (A) Low magnification photomicrograph of hematoxylin and eosin stained cryosection of biceps muscle biopsy, showing marked variation in fiber sizes, and a fiber with several rimmed vacuoles (arrow), highlighted in modified Gomori trichrome stain (inset, arrow), and scattered angular atrophic fibers (arrowheads). Hematoxylin and eosin, scale bar = 100 microns. Inset: High magnification view of region indicated by arrow, scale bar = 25 microns. (B) High magnification view of biceps muscle biopsy cryosection showing moderate variation in fiber size, a minimal increase in endomysial connective tissue, and a fiber containing numerous rimmed vacuoles (arrowhead). Modified Gomori trichrome, scale bar = 50 microns. (C) Higher power photomicrograph showing overly dark angular atrophic fibers typical of neurogenic atrophy (arrows). NADH enzyme histochemistry, scale bar = 100 microns.

Table 1

Clinical summary of the patients.

Clinical presentation	III-3	IV-6
Proximal atrophy	+	+
DTR patella/ankle	0/0	Trace/0
Deltoid (L/R)	1–2/1–2	4+/4+
Biceps (L/R)	4–/4–	4/4
Triceps (L/R)	4–/4–	4+/4+
FDI (L/R)	4/4	5/5
EIP (L/R)	4/4	Not tested
Hip flexors (L/R)	0–1/0–1	4–/4–
Hip extensors (L/R)	0–1/0–1	2/2
Knee flexors (L/R)	0/0	3+/3
Knee extensors (L/R)	1/1	4/4
Ankle dorsiflexion (L/R)	5/5	Limited by tight heel cords
Ankle plantarflexion (L/R)	4–/4–	4/4
Scapula winging	+	+
FVC (% predicted)	42	85
MIP (cm H ₂ O)	–60	–87
Creatine kinase level (U/L)	181	3000

2.2. Haplotype analysis

For each microsatellite marker, amplification of short tandem repeats (STRs) was performed using primers sequences available on the UniSTS database (<http://www.ncbi.nlm.nih.gov/unists>). Forward primers were tagged with 6-FAM and fragment analysis was then performed. Size characterization was performed using Peak Scanner software (Applied Biosystems).

3. Results

3.1. Exome sequencing

Exome sequencing was performed for two affected brothers (Fig. 1A red asterisks; III-1 and III-3) and one unaffected sister (III-2); average coverage depth was 60X. Eleven novel variants shared between the two affected brothers (III-1 and III-3) but not present in the unaffected sister (III-2) were identified (Supplemental Table 1). Included in the list of disease-segregating variants was a variation in the *DNAJB6* gene, c.265T > A, producing a p.Phe89Ile substitution, which is located in the G/F domain of the protein (Fig. 1B). We subsequently focused on *DNAJB6* since this same mutation, as well as other mutations in *DNAJB6*, have been previously associated with LGMD1 [1,5–7]. To confirm the association of this mutation with disease in this family, we performed Sanger sequencing on DNA from the remaining three family members for which a DNA sample was available (Fig. 1A, black asterisks). The c.265T > A mutation in *DNAJB6* was found in all affected and none of the unaffected family members. Combined with the previously reported mutations in *DNAJB6* causing LGMD1D [1,5–7], we determined that

the causative mutation in this family was the c.265T > A/p.Phe89Ile mutation in *DNAJB6*.

3.2. Haplotype analysis

Since a previous study identified the same mutation, p.Phe89Ile, in two other US families (DUK1047 and DUK1701 [6,14]), we wondered if the mutation arose independently in our family or if the three families shared a common origin for the mutation. We performed a haplotype analysis of this region of chromosome 7 to compare the family reported in this study to the two in which this mutation was previously reported (Supplemental Table 2, [6,14]). Microsatellite repeat length is different between this family and the two previously reported families, ruling out a common ancestry, but hinting at a potential mutational hotspot (Supplemental Table 2, [14]).

3.3. Pathology

Muscle pathology in *DNAJB6* dystrophy is characterized by fiber size variation, regenerating fibers, rimmed vacuoles, cytoplasmic inclusions, and disorganized myofibrils, commonly referred to as moth-eaten fibers on NADH-tetrazolium staining [5,6,15]. Rimmed basophilic vacuoles are the key finding on muscle biopsy; however they may also be found in other autosomal dominant LGMDs, specifically LGMD1A [16]. It should be noted that these myopathological changes are consistent with those seen in myofibrillar myopathy (MFM), a clinically and genetically heterogeneous group of muscle disorders with shared muscle pathology characterized by disorganized myofibrils and cytoplasmic desmin-positive inclusions [17]. Upon examination of a biceps muscle biopsy of patient III-3 taken at age 32, we noted key pathological features previously linked to *DNAJB6* dystrophy, including rimmed basophilic vacuoles (Fig. 2). These pathological features combined with our genetic data led us to conclude that the p.Phe89Ile mutation in *DNAJB6* is causative for LGMD1D in this family.

4. Discussion

Using the unbiased technique of exome sequencing, we identified a mutation in *DNAJB6* in a family with LGMD1. LGMD1D was originally described in several Finnish families with linkage to chromosome 7q36 and recently three studies in Finnish, Italian, American, and Japanese families revealed the causative gene to be *DNAJB6* [5–7,15,18]. The nomenclature of LGMD associated with *DNAJB6* mutations is confusing, with some groups utilizing the HUGO Gene Nomenclature Committee's locus designation of LGMD1D, while some use LGMD1E [19] and others use LGMD1D/1E [5];

herein we have used the HUGO gene nomenclature "LGMD1D".

DNAJB6 dystrophy is primarily associated with proximal limb weakness [1,5–7], however distal predominant weakness has also been reported [5]. Onset may occur as early as age 13, but more commonly occurs in the fourth decade of life, and progresses to wheelchair dependence 20–30 years after symptoms begin [1,5–7]. Bulbar, cardiac and pulmonary involvements have been uncommon in reported cases [1,5,6]. Consistent with prior descriptions of *DNAJB6* dystrophy, all patients in this series presented with slowly progressive lower extremity weakness that was predominantly proximal, though the proband also had significant weakness of ankle plantar flexion and some weakness of intrinsic hand muscles. Age of onset was early in all patients reported here, with symptoms present as early as 8 years of age. The proband's markedly reduced forced vital capacity raises the important possibility that ventilatory function can be impaired in LGMD1D.

DNAJB6 is a member of the DNAJ/HSP40 chaperone family and is known to play an important role in suppressing protein aggregation and toxicity of polyglutamine proteins commonly found in various neurodegenerative diseases [20,21]. *DNAJB6* has three domains: an N-terminal J domain, a variable C-terminal domain, and a G/F domain in which all of the mutations linked to LGMD1D (p.Phe89Ile, p.Phe93Leu, p.Phe93Ile, and p.Pro96Arg) have been found [5–7,20]. We identified the previously reported c.265T > A base pair change that resulted in a p.Phe89Ile amino acid substitution in the G/F domain of the protein in all affected members of this pedigree (Fig. 1; Table S1) [6].

We note that we also identified a sequence variation in *TTN*, an exceptionally large gene with mutations causing LGMD2J, a recessive form of LGMD [22], in both affected siblings (III-1 and III-3) but not the unaffected sister (III-2, Table S1). We performed Sanger sequencing and found this variant also segregates with the disease in the six family members for which we had DNA available. Unfortunately, no further DNA samples were available in this pedigree. Patients with some heterozygous *TTN* mutations typically present with tibial muscular dystrophy [22], which presents with a phenotype distinct from that described here. Furthermore, the *TTN* sequence variant that we identified is located in one of the 132 Fibronectin type 3 (FN3) domains, within the highly repetitive region of Ig and FN3 domains, far from any known disease causing mutations [23]. Given that this family presents with pathology and symptoms very similar to previously reported patients with *DNAJB6* mutations and that heterozygous *TTN* mutations generally cause a distinct phenotype, we hypothesize that this *TTN* variation is not responsible for the disease [5–7]. However, we cannot rule out the possibility that the *TTN* sequence variant is playing a role in the clinical presentation in this family, for example in the respiratory

symptoms reported in the proband, as *TTN* mutations can cause hereditary myopathy with early respiratory failure (HMERF) [24]. These findings also highlight the utility of performing exome sequencing compared to candidate gene targeted sequencing.

Our studies corroborate previously published work showing that mutations in *DNAJB6* are associated with LGMD1D. We identified a point mutation in *DNAJB6*, c.265T > A, which results in an amino acid change that was previously shown to be associated with LGMD1D, p.Phe89Ile [6], in an American family of Northern European descent. We performed haplotype analysis of the region surrounding *DNAJB6* and determined that the mutation reported in this study arose independently of the two previously reported families with p.Phe89Ile mutations, and combined with the other mutations reported in the area, this suggests that there may be a mutational hotspot in the G/F domain of *DNAJB6* [5–7]. This work emphasizes the clinical utility of unbiased approaches like exome sequencing for identifying the causative mutations in inherited diseases.

Acknowledgements

We thank the patients and their family for participating in this study. Supported by NIH Director's New Innovator Award DP2OD004417 (A.D.G.), NIH Grants NS065317 (A.D.G.) and NS073660 (A.D.G.). A.D.G. is a Pew Scholar in the Biomedical Sciences, supported by The Pew Charitable Trusts, and a Rita Allen Foundation Scholar. A.R.R. is supported by an Alzheimer's Disease Research Grant from the BrightFocus Foundation. J.D.B. is supported by the NIH-NHGRI Stanford Genome Science training grant. We thank Namita Goyal, MD for clinical data, including patient history and physical exam.

Appendix A. Supplementary data

Supplementary data associated with this article can be found, in the online version, at <http://dx.doi.org/10.1016/j.nmd.2014.01.014>.

References

- [1] Flanigan K. The muscular dystrophies. *Semin Neurol* 2012;32:255–63.
- [2] Hauser M, Horrigan S, Salmikangas P, Torian U, Viles K, Dancel R. Myotilin is mutated in limb girdle muscular dystrophy 1A. *Hum Mol Genet* 2000;9:2141–7.
- [3] Muchir A, Bonne G, van der Kooij A, van Meegen M, Baas F, Bolhuis P. Identification of mutations in the gene encoding lamins A/C in autosomal dominant limb girdle muscular dystrophy with atrioventricular conduction disturbances (LGMD1B). *Hum Mol Genet* 2000;9:1453–9.
- [4] Minetti C, Sotgia F, Bruno C, Scartezzini P, Broda P, Bado M. Mutations in the caveolin-3 gene cause autosomal dominant limb-girdle muscular dystrophy. *Nat Genet* 1998;18:365–8.
- [5] Harms M, Sommerville R, Allred P, Bell S, Ma D, Cooper P. Exome sequencing reveals *DNAJB6* mutations in dominantly-inherited myopathy. *Ann Neurol* 2012;71:407–16.
- [6] Sarparanta J, Jonson P, Golzio C, Sandell S, Luque H, Screen M. Mutations affecting the cytoplasmic functions of the co-chaperone *DNAJB6* cause limb-girdle muscular dystrophy. *Nat Genet* 2012;44:450.
- [7] Sato T, Hayashi Y, Oya Y, Kondo T, Sugie K, Kaneda D. *DNAJB6* myopathy in an Asian cohort and cytoplasmic/nuclear inclusions. *Neuromuscul Disord* 2013;23:269–76.
- [8] Torella A, Fanin M, Mutarelli M, Peterle E, Del Vecchio Blanco F, Rispoli R. Next-generation sequencing identifies transportin 3 as the causative gene for LGMD1F. *PLoS One* 2013;8:e63536.
- [9] Melia MJ, Kubota A, Ortolano S, Vilchez JJ, Gamez J, Tanji K. Limb-girdle muscular dystrophy 1F is caused by a microdeletion in the transportin 3 gene. *Brain* 2013;136:1508–17.
- [10] Langmead B, Salzberg S. Fast gapped-read alignment with bowtie 2. *Nat Methods* 2012;9:357–9.
- [11] Li H, Handsaker B, Wysoker A, Fennell T, Ruan J, Homer N. The sequence alignment/map format and SAMtools. *Bioinformatics* 2009;25:2078–9.
- [12] DePristo M, Banks E, Poplin R, Garimella K, Maguire J, Hartl C. A framework for variation discovery and genotyping using next-generation DNA sequencing data. *Nat Genet* 2011;43:491–8.
- [13] Wang K, Li M, Hakonarson H. ANNOVAR: functional annotation of genetic variants from high-throughput sequencing data. *Nucleic Acids Res* 2010;38.
- [14] Speer MC, Vance JM, Grubber JM, Lennon Graham F, Stajich JM, Viles KD. Identification of a new autosomal dominant limb-girdle muscular dystrophy locus on chromosome 7. *Am J Hum Genet* 1999;64:556–62.
- [15] Sandell S, Huovinen S, Sarparanta J, Luque H, Raheem O, Haapasalo H. The enigma of 7q36 linked autosomal dominant limb girdle muscular dystrophy. *J Neurol Neurosurg Psychiatry* 2010;81:834–9.
- [16] Olive M, Goldfarb L, Shatunov A, Fischer D, Ferrer I. Myotilinopathy: refining the clinical and myopathological phenotype. *Brain* 2005;128:2315–26.
- [17] De Bleeker J, Engel A, Ertl B. Myofibrillar myopathy with abnormal foci of desmin positivity. II. Immunocytochemical analysis reveals accumulation of multiple other proteins. *J Neuropathol Exp Neurol* 1996;55:563–77.
- [18] Hackman P, Sandell S, Sarparanta J, Luque H, Huovinen S, Palmio J. Four new Finnish families with LGMD1D; refinement of the clinical phenotype and the linked 7q36 locus. *Neuromuscul Disord* 2011;21:338–44.
- [19] Bushby K, Beckmann J. The 105th ENMC sponsored workshop: pathogenesis in the non-sarcoglycan limb-girdle muscular dystrophies, Naarden, April 12–14, 2002. *Neuromuscul Disord* 2003;13:80–90.
- [20] Hageman J, Rujano M, van Waarde M, Kakkar V, Dirks R, Govorukhina N. A DNAJB6 chaperone subfamily with HDAC-dependent activities suppresses toxic protein aggregation. *Mol Cell* 2010;37:355–69.
- [21] Udan-Johns M, Bengoechea R, Bell S, et al. Prion-like nuclear aggregation of TDP-43 during heat shock is regulated by HSP40/70 chaperones. *Hum Mol Genet* 2014;23:157–70.
- [22] Hackman J, Vihola A, Udd A. The role of titin in muscular disorders. *Ann Med* 2003;35:434–41.
- [23] Kontogianni-Konstantopoulos A, Ackermann MA, Bowman AL, Yap SV, Bloch RJ. Muscle giants: molecular scaffolds in sarcomerogenesis. *Physiol Rev* 2009;89:1217–67.
- [24] Toro C, Olive M, Dalakas MC, Sivakumar K, Bilbao JM, Tyndel F. Exome sequencing identifies titin mutations causing hereditary myopathy with early respiratory failure (HMERF) in families of diverse ethnic origins. *BMC Neurol* 2013;13:29.